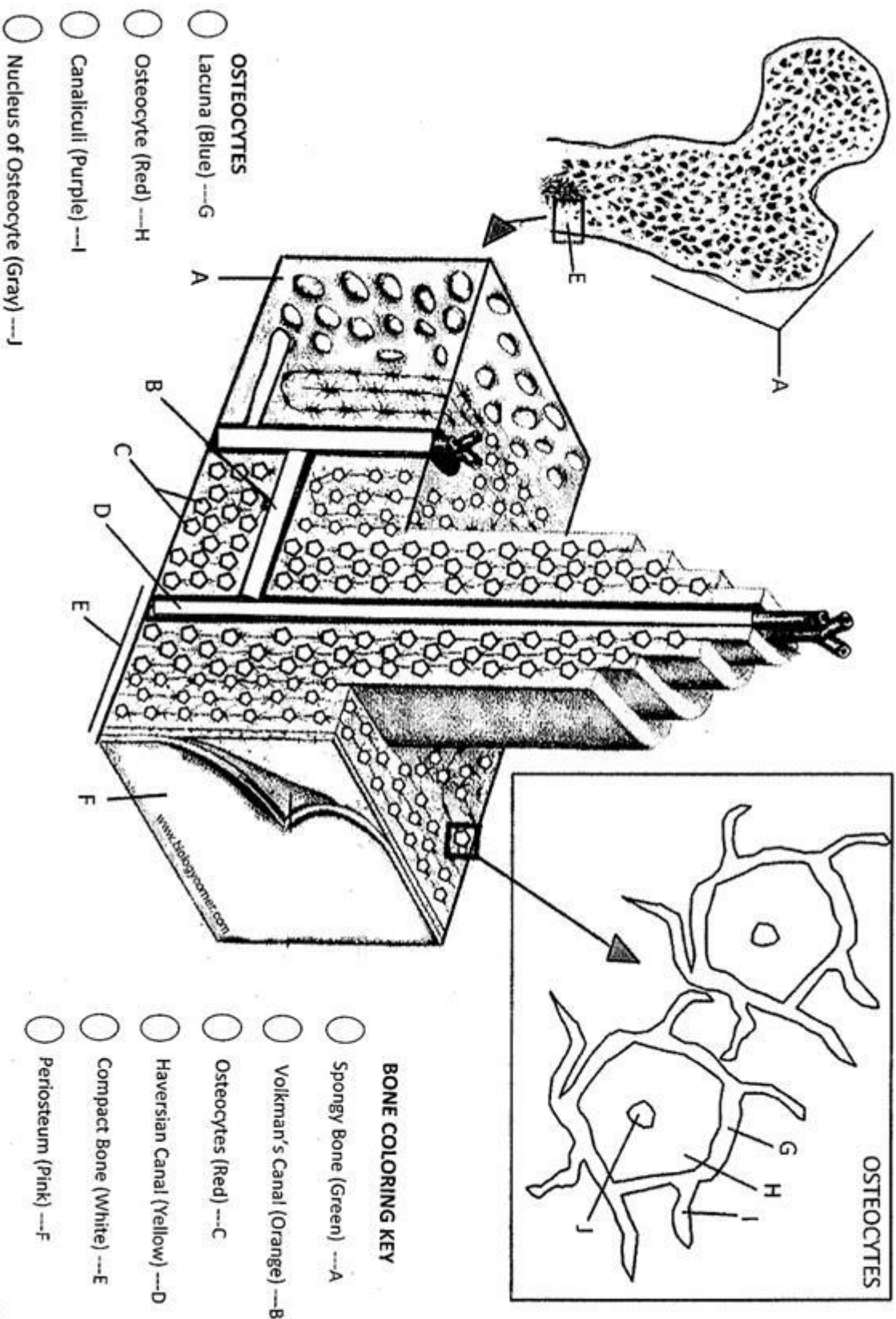


BONE MATRIX COLORING

Name



Anatomy of a Bone -- Coloring

Name _____

EPIPHYSIS (end) (a), EPIPHYSIAL LINE (a) - purple

The epiphysis is the end of a long bone. Externally it has a thin layer of compact bone, while internally the bone is cancellous. The Epiphysis is capped with articular cartilage.

DIAPHYSIS (shaft) (b)

The diaphysis is the shaft of the long bone. It has compact bone with a central cavity.

ARTICULAR CARTILAGE (c) - green

The articular cartilage is found on the ends of long bones. It is smooth, slippery, and bloodless.

PERIOSTEUM (d) - dark blue

Periosteum is a fibrous, vascular, sensitive life support covering for bone. It provides nutrient-rich blood for bone cells and is a source of bone-developing cells during growth or after a fracture. **CANCELLOUS (spongy) BONE (e) and MARROW (e) - light blue**

The cancellous bone appears as tiny beams of bone arranged like a lattice. Red marrow packs the spaces between beams.

COMPACT BONE (f) - pink

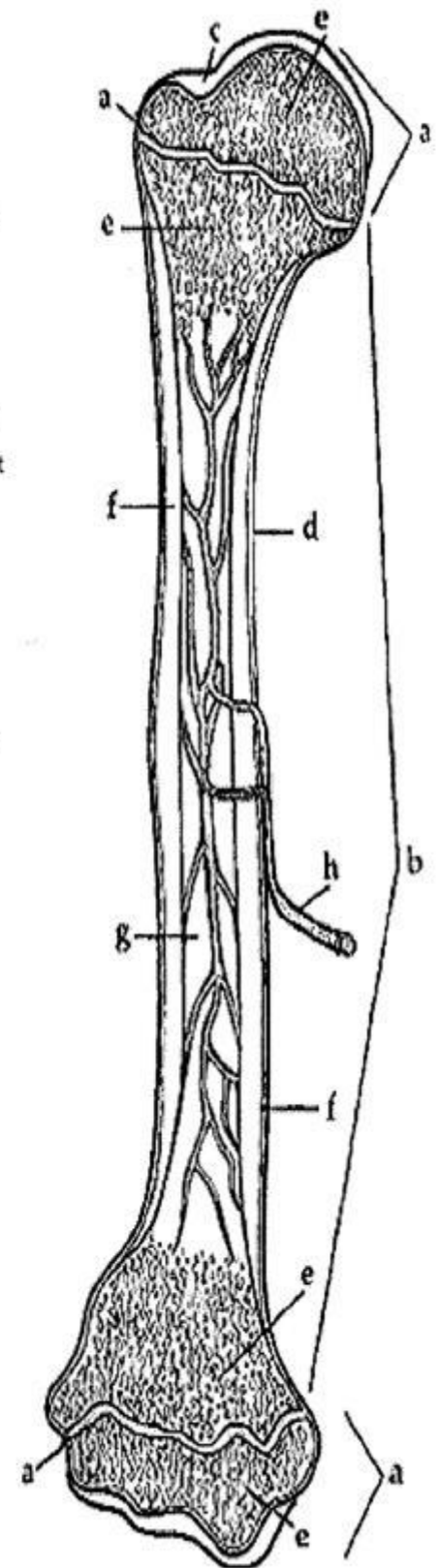
The compact bone is a dense bone found in the diaphysis. Its repeated pattern is arranged in concentric layers of solid bone tissue.

MEDULLARY CAVITY (g), YELLOW MARROW (g) - yellow

The medullary cavity of the diaphysis serves to lighten bone weight and provide space for its marrow.

NUTRIENT ARTERY (h) - red

Each long bone contains a tunnel in its shaft for the passage of a nutrient artery, which supplies the shaft.



1. Where do you find yellow marrow? _____
2. What type of bone is arranged in concentric layers? _____
3. Where do you find red marrow? _____
4. What is the end of the bone called? _____
5. Spongy bone is also called _____ bone.