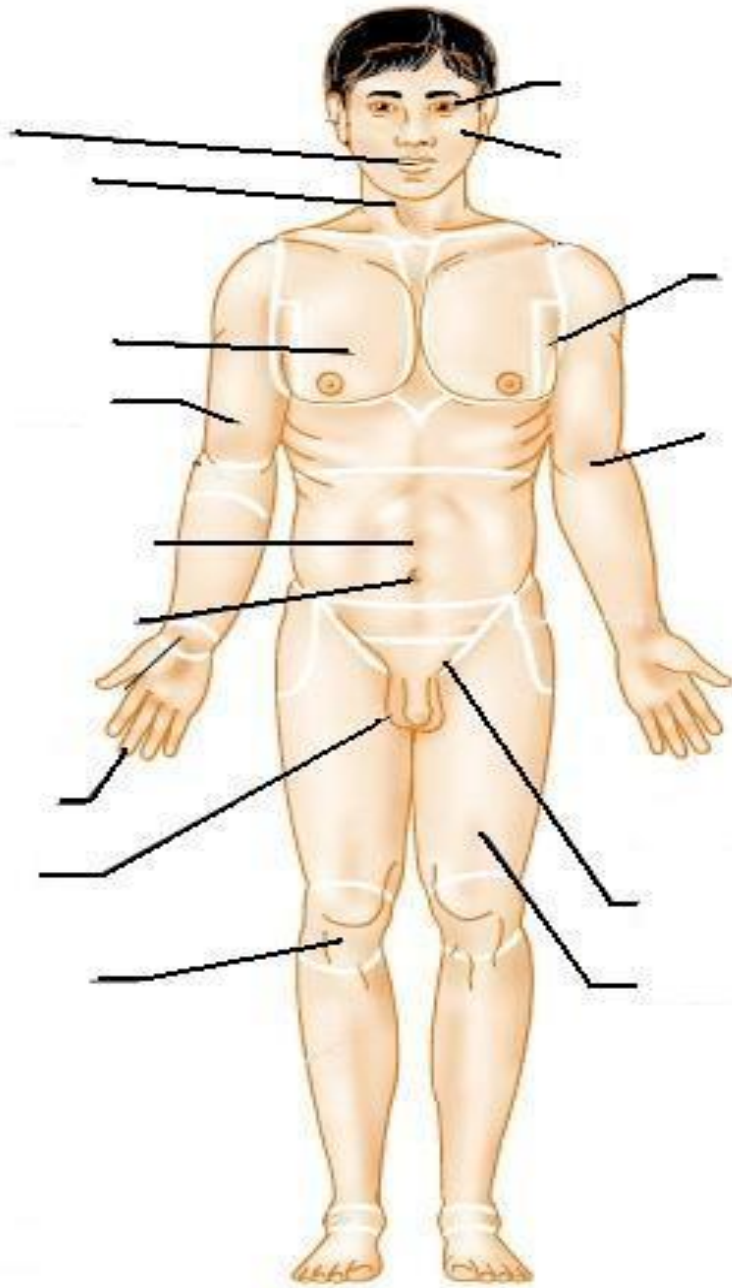
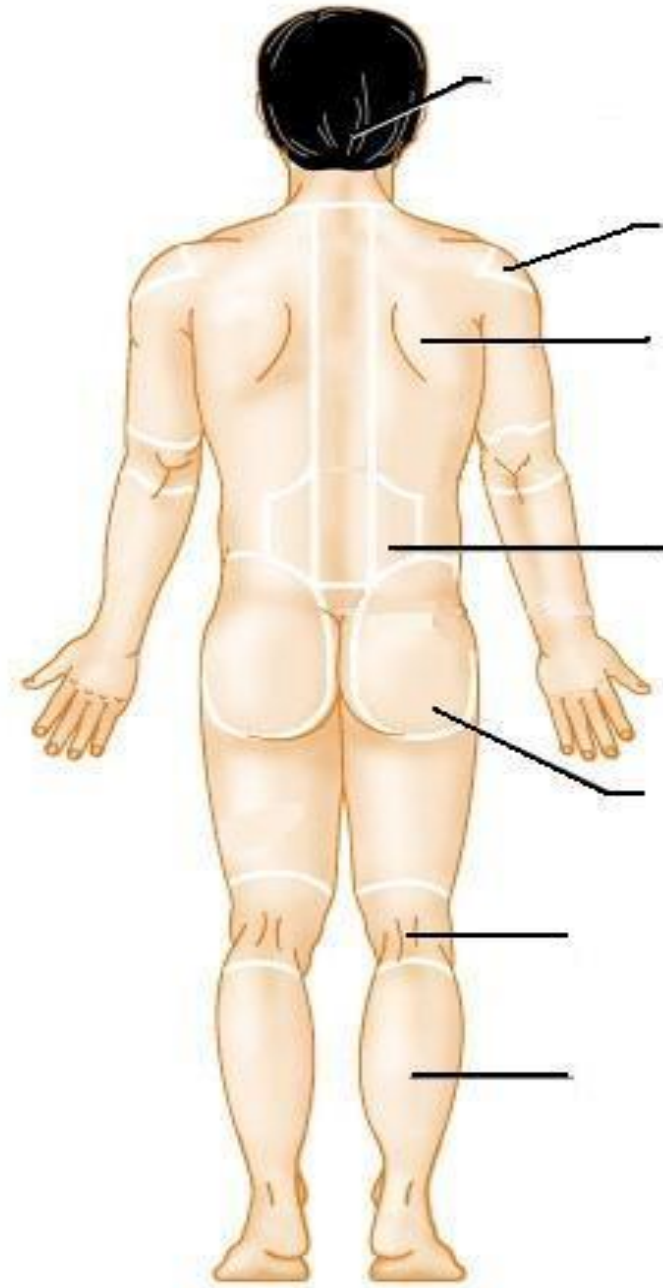


Surface Anatomy Body Regions



(a) Anterior



(b) Posterior